


# CONTEMPORARY TRANSORAL SURGERY FOR PRIMARY HEAD AND NECK CANCER



**Michael L. Hinni, MD**  
**David G. Lott, MD**



---

# CONTENTS

Foreword by M. Stuart Strong	vii
Foreword by Geza J. Jako	ix
Contributors	xi
<b>1 History of Transoral Surgery</b> <i>Steven M. Zeitels</i>	<b>1</b>
<b>2 Transoral Endoscopic (Inside-Out) Anatomy</b> <i>Michael L. Hinni, David G. Lott, and Eric J. Moore</i>	<b>11</b>
<b>3 Instrumentation and General Techniques</b> <i>Michael L. Hinni and David G. Lott</i>	<b>25</b>
<b>4 Margin Analysis and Pathologic Considerations</b> <i>Michael L. Hinni and Eric J. Moore</i>	<b>37</b>
<b>5 Transoral Surgery for Oral Cavity Cancer</b> <i>Parul Sinha and Bruce H. Haughey</i>	<b>49</b>
<b>6 Transoral Surgery for Tonsil and Palatal Carcinoma</b> <i>Brittany E. Howard, Bruce H. Haughey, and Michael L. Hinni</i>	<b>65</b>
<b>7 Transoral Surgery for Base-of-Tongue Carcinoma</b> <i>Eric J. Moore and Bruce H. Haughey</i>	<b>83</b>
<b>8 Transoral Surgery for Supraglottic Larynx Cancer</b> <i>David G. Lott and Michael L. Hinni</i>	<b>109</b>
<b>9 Transoral Surgery for Glottic and Subglottic Larynx Cancer</b> <i>David G. Lott, Matthew H. Rigby, and S. Mark Taylor</i>	<b>127</b>
<b>10 Transoral Surgery for Hypopharyngeal Cancer</b> <i>Thomas H. Nagel, David G. Lott, and Bruce H. Haughey</i>	<b>149</b>
<b>11 Complications of Transoral Surgery for Head and Neck Cancer</b> <i>Michael L. Hinni and Eric J. Moore</i>	<b>159</b>
<b>12 Transoral Surgery in the Multidisciplinary Setting</b> <i>Samir H. Patel and Wade Thorstad</i>	<b>173</b>
<b>13 Transoral Surgery for Chemoradiation Failures</b> <i>Matthew H. Rigby, Brian Nussenbaum, Michael L. Hinni, and David G. Lott</i>	<b>189</b>
<b>14 Oncologic Outcomes Comparing Transoral Laser Microsurgery, Open Surgery, and Chemoradiation</b> <i>Jason T. Rich and Bruce H. Haughey</i>	<b>199</b>

---

<b>15</b>	<b>Functional Outcomes of Transoral Surgery</b>	<b>213</b>
	<i>David G. Lott, Lisa Crujido, and Brian Nussenbaum</i>	
<b>16</b>	<b>Reconstruction Techniques for Transoral Surgery Defects</b>	<b>227</b>
	<i>Eric J. Moore and David G. Lott</i>	
	Index	239



---

# FOREWORD

This book on transoral surgery is a very timely compendium of what has become an important component of the care of patients with problems of the aerodigestive tract. We have come a long way since the 1965 November meeting of the New England Otolaryngology Society at Boston University Medical School.

I happened to have been the president when G. David King, MD, of the Lahey Clinic presented a paper on "The Transoral Approach to Cancer of the Oral Cavity and Oropharynx." It stood out as a landmark concept amidst other papers on the composite approach. At that time, the concept was treated with great suspicion, if not scorn, by various members of the head and neck fraternity!

I am delighted to see the heavy emphasis on anatomical detail, the pathological aspects of tumor biology and adequacy of tumor margins, as well as the importance of adequate exposure and the enthusiastic participation of a flexible anesthesiologist.

The illustrations are superb and always relevant. The thought flow is very good as one moves from one area to another, in spite of contributions from multiple authors.

Most importantly, there is a very necessary awareness of alternative approaches and the need for multidisciplinary involvement at times. Every approach has its limitations!

This book will be an important part of the library of the next generation of otolaryngology-head and neck surgeons.

—M. Stuart Strong, MD  
Professor Emeritus  
Department of Otolaryngology-Head  
and Neck Surgery  
Boston University Medical School



---

# CONTRIBUTORS

**Lisa Crujido, MS, CCC-SLP**

Department of Otorhinolaryngology  
Mayo Clinic Arizona  
Phoenix, Arizona  
*Chapter 15*

**Bruce H. Haughey, MB, ChB, FACS, FRACS**

Kimbrough Professor and Director  
Head and Neck Surgical Oncology  
Department of Otolaryngology-Head and Neck  
Surgery  
Washington University in St. Louis  
School of Medicine  
St. Louis, Missouri  
*Chapters 5, 6, 7, 10, and 14*

**Michael L. Hinni, MD**

Professor and Consultant  
Chair, Department of Otolaryngology-Head and  
Neck Surgery  
Program Director, Otolaryngology Residency  
Program  
Mayo Clinic College of Medicine  
Phoenix, Arizona  
*Chapters 2, 3, 4, 6, 8, 11, and 13*

**Brittany E. Howard, MD**

Department of Otolaryngology-Head and Neck  
Surgery  
Mayo Clinic Arizona  
Phoenix, Arizona  
*Chapter 6*

**David G. Lott, MD**

Assistant Professor and Consultant  
Director, Voice Program  
Director, Head and Neck Regeneration Laboratory  
Department of Otolaryngology-Head and Neck  
Surgery  
Mayo Clinic College of Medicine  
Phoenix, Arizona  
*Chapters 2, 3, 8, 9, 10, 13, 15, and 16*

**Eric J. Moore, MD**

Consultant, Otolaryngology-Head and Neck  
Surgery  
Mayo Clinic  
Rochester, Minnesota  
*Chapters 2, 4, 7, 11, and 16*

**Thomas H. Nagel, MD**

Assistant Professor and Senior Associate  
Consultant  
Department of Otolaryngology-Head and Neck  
Surgery  
Mayo Clinic College of Medicine  
Phoenix, Arizona  
*Chapter 10*

**Brian Nussenbaum, MD, FACS**

Christy J. & Richard S. Hawes III Professor  
Vice Chair for Clinical Affairs  
Department of Otolaryngology-Head and Neck  
Surgery  
Washington University in St. Louis  
School of Medicine  
St. Louis, Missouri  
*Chapters 13 and 15*

**Samir H. Patel, MD**

Assistant Professor  
Mayo Clinic in Arizona  
Department of Radiation Oncology  
Scottsdale, Arizona  
*Chapter 12*

**Jason T. Rich, MD**

Assistant Professor  
Department of Otolaryngology-Head and Neck  
Surgery  
Washington University in St. Louis  
School of Medicine  
St. Louis, Missouri  
*Chapter 14*

---

**Matthew H. Rigby**

Clinical Fellow  
Advanced Head and Neck Microvascular and  
Reconstructive Surgery  
Mayo Clinic Arizona  
Scottsdale, Arizona  
*Chapters 9 and 13*

**Parul Sinha, MBBS, MS**

Research Fellow  
Head and Neck Surgical Oncology  
Washington University in St. Louis  
School of Medicine  
St. Louis, Missouri  
*Chapter 5*

**S. Mark Taylor, MD, FRCS(C), FACS**


Professor and Deputy Head  
Director, Head and Neck Oncology Program  
Dalhousic University  
Halifax, Nova Scotia, Canada  
*Chapter 9*

**Wade L. Thorstad, MD**

Associate Professor, Radiation Oncology  
Chief, Head and Neck Service  
Department of Radiation Oncology  
Washington University School of Medicine  
St. Louis, Missouri  
*Chapter 12*

**Steven M. Zeitels, MD, FACS**

Eugene B. Casey Professor of Laryngeal Surgery  
Harvard Medical School  
Director, Center for Laryngeal Surgery  
Massachusetts General Hospital  
Boston, Massachusetts  
*Chapter 1*



---

# 2

## TRANSORAL ENDOSCOPIC (INSIDE-OUT) ANATOMY

Michael L. Hinni, David G. Lott, and Eric J. Moore

### Introduction

---

Learning anatomy has been a classic rite of passage in medical education for centuries. Although surgeons may be justified in believing that their understanding of anatomy is superior to nonsurgeons, they also should recognize that the anatomy they know so well has to be in some measure learned again as new surgical approaches are developed and new surgical tools for visualization are created. Evolution in surgical technique is normal and expected. As has been described in the previous chapter, significant strides in surgical instrumentation, exposure, and magnification have allowed surgeons, particularly head and neck surgeons, to revolutionize the practice of medicine. There have been long periods throughout history where very little improvement in technique was realized for generations and other periods where (as is the case currently) rapid changes are under way. References will be few. Few exist. Much is adapted from traditional anatomic work inverted, combined with observation in the cadaver laboratory and operating room.

Despite this, modern medical students still learn their anatomy in a classroom or with online 2-dimensional modules. It is a rite of passage to then advance into the cadaver laboratory and

do a cadaveric dissection. This cadaveric dissection may or may not emphasize head and neck anatomy, but what is taught begins with the skin layer. The student then proceeds below the skin to explore the muscular structures and vascular structures of the neck, working from the outside toward the inside. Ocular anatomy, ear anatomy, and the balance of head and neck anatomy are thus taught. Later in medical training, the student or resident begins to operate on living people (simulation has yet to define its place in head and neck surgical anatomy training) where an incision is made on the skin and the skin is elevated in the subplatysmal layer. The fascial planes of the neck and/or jaws are exposed. The patient's anatomy is thus learned from the exterior toward the interior. Physicians who do not regularly operate in the neck tend to rapidly lose memory of the complex head and neck anatomy.

During the practice of transoral head and neck surgery, irrespective if the surgeon is employing a video endoscope, microscope, or robotic 3-dimensional camera, the anatomy is approached from the inside out. Although traditional surgeons graduating from otolaryngology-head and neck surgery residency or fellowships may feel that they know their anatomy "inside out," they actually know it from the "outside in." True inside-out anatomy is all together different and must be relearned,

and this is the purpose of this chapter. Recognizing anatomy when there is limited access, no or small incisions, when the anatomy is distorted by tumor, retractors, and/or endoscopes all create challenges. Mastering this inside-out anatomy is exceedingly important, difficult to recognize, and perhaps even more difficult to teach.<sup>1</sup>

No discussion of anatomy should exclude general body and head and neck anatomy. During a history, the surgeon can discover if the patient is morbidly obese or has had cervical fusions, previous neck surgery, previous jaw surgery, dental extractions, or obstructive sleep apnea. The examination can reveal the same in addition to class I occlusion and mandibular hypoplasia, relative macroglossia, cervical fibrosis or stiffness, or ankyloglossia. The patient's general anatomy must be considered first and is a crucial aspect to tumor exposure and ultimate respectability. Dr. Bruce Haughey and associates at Washington University in St Louis cleverly describe the 8 Ts of exposure (Table 2-1).<sup>2</sup> To these 8, we would like to add tethering and time. Both previous treatment and tumor fibrosis can tether the tongue or other soft-tissue structures in the oral cavity or oropharynx. Furthermore, compression time from retractor or laryngoscope blades can create swelling during the endoscopic operation, gradually limiting exposure. The original 8 Ts include teeth

(the presence of teeth), the anterior projection of the teeth, or the size of the teeth, which can all be limiting factors to exposure. The size of the tongue and relative macroglossia is also an important factor. The tilt of the patient's head as well as the size and invasiveness and extent of the tumor can limit surgeon's access. Transverse dimensions of the mandible, as well as the presence of tori in the mandible or on the palate, can at times limit exposure sometimes significantly (Figure 2-1). Occasionally, the surgeon will find that the exposing retractor or laryngoscope of choice will not fit between the bodies of the mandible. Obviously, trismus either from pain or tumor invasion, as well as fibrosis (eg, from previous chemoradiotherapy), can significantly limit exposure, as can prior treatment of any kind.

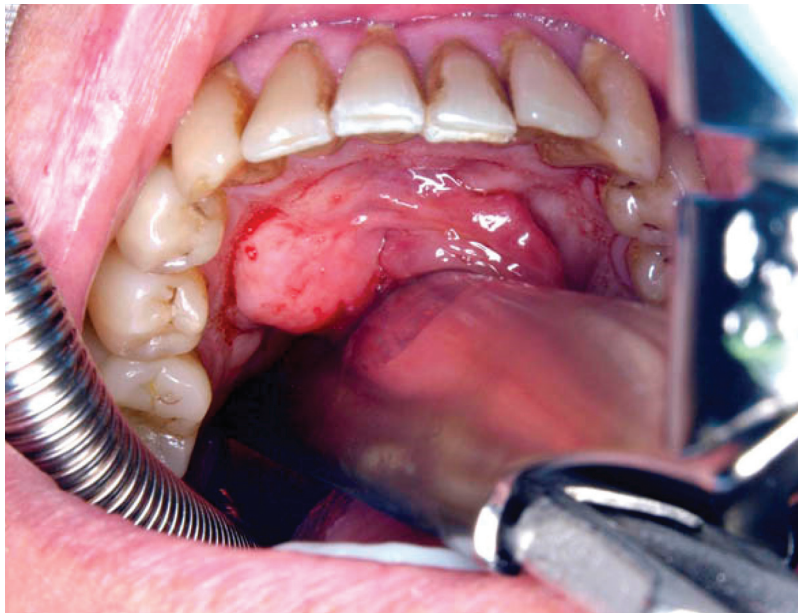
Although it is uncommon, some tumors, even though they may be fairly small and particularly if they are significantly large, simply cannot be removed transorally due to the 10 Ts we have described above, and at times the operating surgeon simply cannot know this ahead of time. In our experience, it is quite unusual to bring a patient to the operating room and not be able to remove his or her tumor completely. If the robot is being used as the primary instrument platform to resect the tumor, the surgeon may struggle with larger T-stage tumors, largely due to patient selection. The number of tumors that are planned to be removed with the robot but cannot be range from less than 5% to as many as 25%.<sup>3,4</sup> In our experience, if the robotic platform cannot access or remove all of the cancer and the surgeon switches to a transoral laser microsurgical setup with smaller solid-bore laryngoscopes, then tumor clearance generally can be accomplished.

The surgeon needs to study the preoperative computed tomography (CT) scans. Important patient anatomy (both normal and abnormal) can often be realized this way. The vascular anatomy in particular can be studied together in relation to the tumor (within tumor, adjacent to tumor, or separate from tumor) (Figure 2-2). This can prepare the surgeon for vascular control during the endoscopic procedure. Similarly, aberrant vessels that are not part of the disease process can be identified (Figure 2-3). On occasion, studying

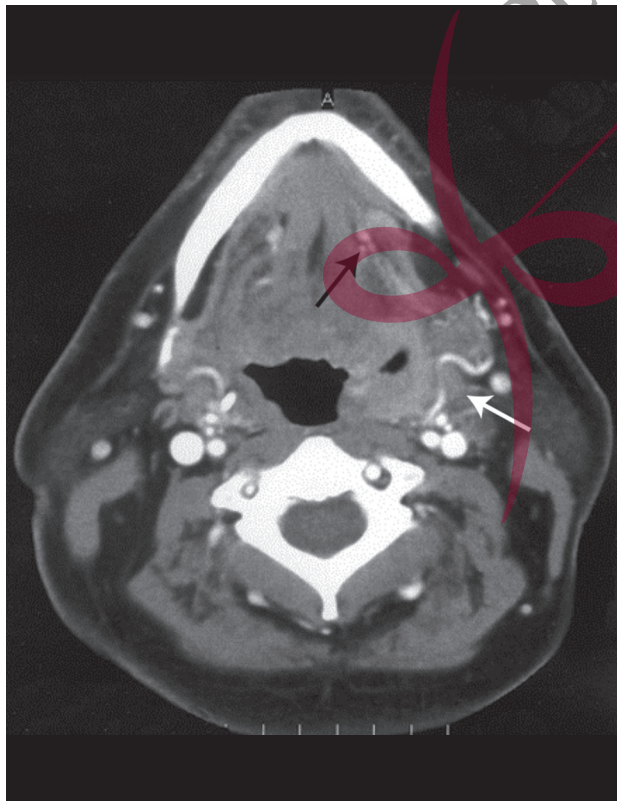
**Table 2-1.** The 10 Ts of Exposing Cancer During Transoral Surgery

Teeth
Tongue
Tilt
Transverse dimension
Tori
Trismus
Treatment
Tumor
Tethering
Time

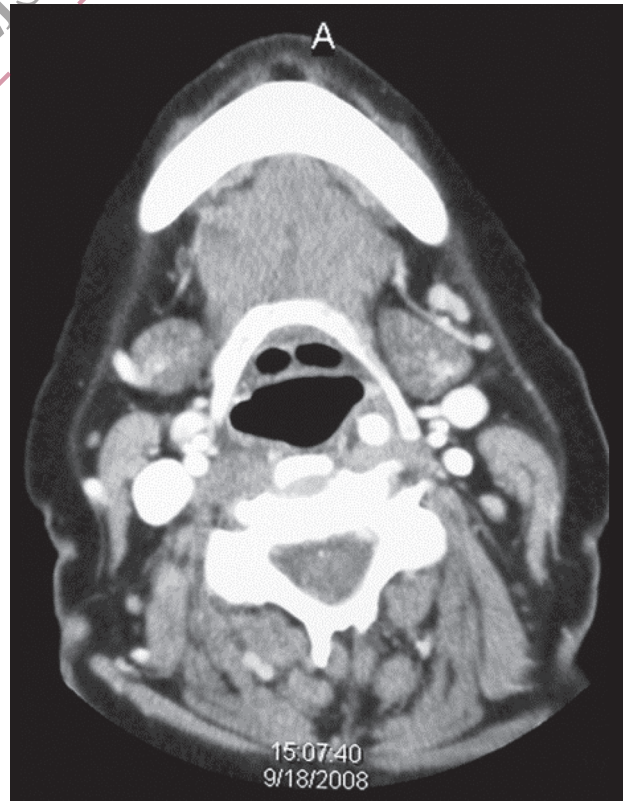



**Figure 2-1.** Mandibular tori preventing anterior exposure of the larynx.



**Figure 2-2.** CT scan of left lateral pharyngeal carcinoma. Note tortuous facial artery on the deep side of the tumor (*white arrow*). More anteriorly, the lingual artery is evident (*black arrow*).



**Figure 2-3.** Preoperative CT scan. Note the carotid artery within the hyoid bone, creating a submucosal hypopharyngeal mass.

the CT scan can determine a contraindication to transoral surgery in general. One example is the merging of the primary tumor with the lymphatics in the neck, often sandwiching the great vessels in between. Most endoscopic surgeons would concur that if the external carotid system needs to be resected together with disease that has fused with the primary tumor, a significant defect will result, requiring pharyngeal reconstruction. Such cases fortunately are uncommon but are probably best served with traditional open surgery so that reconstruction can be more easily applied.

### Vascular Control

Generally, during endoscopic resections, bleeding is related to arteries and not to the veins. The veins tend to be quite easy to control with endoscopic cauterization, either monopolar or bipolar, or with surgical clips. (When a patient presents with a delayed postoperative bleed, the source is almost never a venous one.) Thus, we will limit the discussion to the inside-out anatomy of the head and neck arteries. It is critical that the transoral endoscopic head and neck surgeon learn the location of these arteries. A detailed list that the experienced surgeon should be able to identify from inside out can be found in Table 2-2. The location of these arteries can be determined by a careful evaluation of the preoperative imagery and by a recognition of their typical location relative to the other head and neck structures. As such, the inside-out anatomy of the arteries, as well as those of corresponding cranial nerves, is reviewed in the following organ-specific descriptions (Table 2-3).

### Larynx

Most head and neck surgeons and many general otolaryngologists routinely treat glottic cancers transorally. In the glottis, bleeding is easily controlled with various laser wavelengths, cautery when necessary, or simple topical vasoconstrictive

**Table 2-2.** Learn Your Anatomy Inside Out: Arteries

Arteries
Branches
Descending palatine a.
Ascending pharyngeal a.
Facial a.
Ascending palatine br.
Tonsillar br.
Lingual a.
Dorsal lingual br.
Superior thyroid a.
Superior laryngeal br.: anterior and posterior
Cricothyroid br.
Inferior thyroid a.
Inferior laryngeal a.

**Table 2-3.** Learn Your Anatomy Inside Out: Nerves

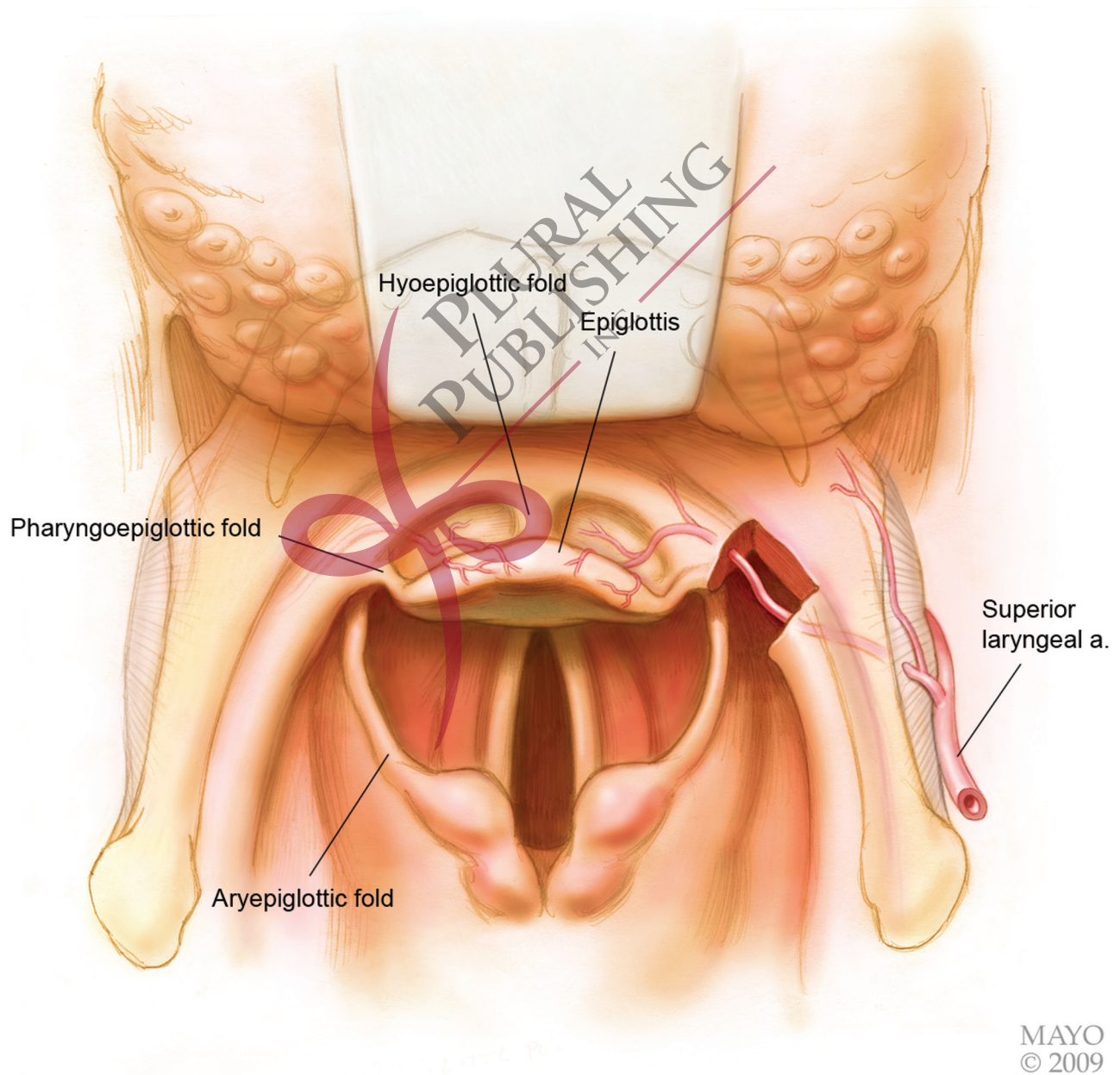
Nerve
Lingual
Glossopharyngeal
Hypoglossal
Superior laryngeal
Recurrent laryngeal

agents. Problems can arise, however, with glottic carcinomas that extend laterally into the ventricle. These are best exposed by incising or removal the false cord. Perhaps first described in 1974, there is a reliable branch of the superior laryngeal artery running from posterior to anterior within the undersurface of the false cord.<sup>5</sup> This artery is generally laterally based and can be in the paraglottic space just deep to the mucosa, where the mucosa within the ventricle is juxtaposed to the internal perichondrium of the thyroid ala. Monopolar or

bipolar cautery can generally control this vessel, but occasionally it may require surgical clips.

More superiorly in the larynx are the critical superior laryngeal artery and vein. During transoral surgery for carcinomas that involve the supraglottis, identifying and controlling the superior laryngeal artery is an important and often life-

saving event (Figures 2–4 and 2–5). We encourage all surgeons during resections of the supraglottic larynx (whether this is due to extension of a lateral pharyngeal wall carcinoma, hypopharyngeal carcinoma, or primary laryngeal carcinoma) to carefully identify the superior laryngeal artery.<sup>6</sup> If the reader will consider anatomy from the



**Figure 2–4.** Note location of the internal branch of the superior artery within the pharyngoepiglottic fold.