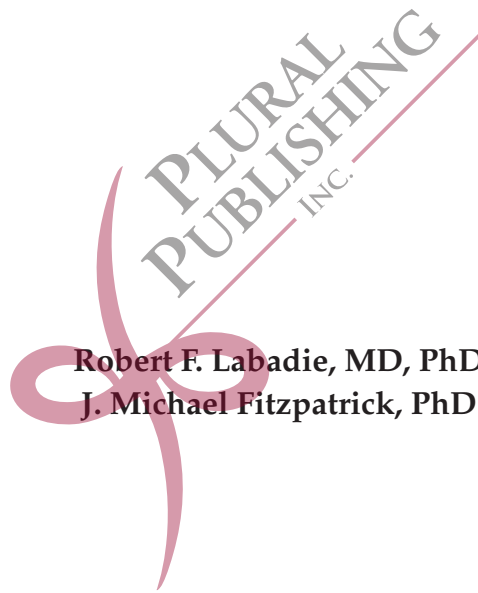

■ IMAGE-GUIDED SURGERY ■

Fundamentals and Clinical Applications in Otolaryngology



Robert F. Labadie, MD, PhD
J. Michael Fitzpatrick, PhD



CONTENTS

<i>Introduction</i>	<i>ix</i>
<i>Acknowledgments</i>	<i>xi</i>
1 Brief History of Image-Guided Surgery	1
Overview of How Image-Guided Surgery Works	1
The Evolution of IGS	3
Images	3
Putting It All Together: CT and MRI in IGS	12
References	21
2 CT and MRI	25
How CT Works	25
Intraoperative CT Scanners	30
Stationary CT Scanners	30
Portable CT Scanners	31
MRI	40
How MRI Works	40
Why Is Understanding Imaging Important in Using IGS?	70
Inaccuracy in Images	70
2D Presentation of 3D Images	71
References	73
3 Tracking Systems	75
Overview	75
Optical Tracking	78
Electromagnetic (EM) Tracking	90
Summary	97
References	97
4 Registration	99
Fiducial Markers and Points	100
Skin-Affixed, Fiducial Markers and Points	100
Bone-Affixed, Fiducial Markers and Points	102
Rigid Point Registration	107
Surface Registration	109
Accuracies for Various Types of Fiducials	112
Fiducials During Navigation	113
Fusion	113
References	114

5	Error Analysis	117
	Extrinsic Versus Intrinsic Error	118
	Fiducial Localization Error (FLE)	119
	Fiducial Registration Error (FRE)	120
	Target Registration Error (TRE)	121
	Error Relationships	122
	Relating TRE to FLE	122
	Relationships Involving FRE	127
	Probe Localization Error (PLE)	128
	Stubborn Myths	129
	Myth 1: FRE Is an Indicator of TRE	130
	Myth 2: Dropping a Fiducial Will Increase Accuracy	134
	Myth 3: Planar Fiducial Configurations Are Bad	137
	Summary	137
	References	138
6	Best Practices for Use of IGS	141
	Who Is Using IGS?	141
	Is IGS Safer for Patients?	142
	Does IGS Help Make Better Surgeons?	144
	Professional Society Position Statements	144
	Is IGS Financially Sustainable?	146
	Less Litigation?	147
	Overview	147
	References	148
7	Surgical Systems	151
	Current FDA-Cleared IGS for ENT	153
	Medtronic	153
	Brainlab	162
	Clinical Accuracy of Electromagnetic (EM) Tracking Systems	171
	Stryker	172
	Smaller IGS Companies	180
	Fiagon	180
	ClaroNav	181
	Summary	181
	References	183
8	What Does the Future Hold?	185
	Computer-Assisted Navigation	185
	Augmented Reality	187
	Visual Augmented Reality	189
	Nonvisual Augmented Reality	190

Robots	193
History	194
History of Autonomous Robots	194
Current FDA-Cleared Autonomous Robots	197
What Autonomous Robots Does Otolaryngology Need?	197
Conclusions	202
References	203
<i>Index</i>	205



INTRODUCTION

A tool is only as good as its human operator. Perhaps this truth is most evident in art, where a masterpiece may be created by a talented operator using very simple, basic tools. While Michelangelo produced the masterpiece that graces the ceiling of the Sistine Chapel with mere brushes, paint, and plaster, the authors of this work would be hard pressed to use these same tools to create anything considered art!

Image guidance for surgical interventions is a tool, and it too is only as good as its human operator. Proper use of an image-guidance system is vital to both safety and efficacy in the operating room, and because these systems are becoming so widespread and at the same time are becoming so sophisticated, there is a real danger that their human operators may become captive to the technology instead of mastering it. The authors have watched this situation develop over a period of some 25 years, slowly at first but much more rapidly in the last 5 or 10 years. And, in that quarter century, the following theme has emerged: running through all this complexity is a common theoretical thread that, once grasped, will subdue the technology and make these marvelous tools far easier to master. Furthermore, understanding the theory of image guidance does not require an advanced degree in engineering or physics. It is our contention that these ideas can be understood by anyone who is willing to learn.

To prove our claim and to help surgeons navigate the bewildering array of features, manuals, guidelines, warn-

ings, and scientific publications in this field, we have written this book to explain the theory behind the technology and to present the current state of the art in the context of clinical applications. While some clinicians may at first be put off by the inclusion of theory in this work, we have found that it is vital to understanding both the power and the limits of this emerging technology, and we have worked hard to make it accessible. Leonardo da Vinci was unaware of the rapid deterioration of the egg-based tempura he used to paint the *Last Supper*, and as result that masterpiece is no longer with us in its full glory. Likewise, the skull-base surgeon who is unaware of the limitations of image-guided surgery may either not use the technology to its full capacity or, worse, use it in a way that is dangerous.

To make it feasible for the busy surgeon to learn the basic foundations of image guidance without devoting an inordinate amount of time to it, we have done our best to trim all technical descriptions to their bare essentials. To make it easier to understand these descriptions, we have augmented them with clarifying explanations, analogies, and examples, such that all clinicians should be able to understand the technology. In addition, scattered through the book we have included boxed text highlighted in light blue-gray to provide additional details for the interested reader. These details tell “the rest of the story” (quoting the late Paul Harvey) but can be skipped without interrupting the flow and content of the text. Finally, we have included plenty

of figures to help illustrate our points and make them simpler to absorb. But, at the same time, in keeping with our underlying goal of providing the necessary information to help clinicians understand the technology such that they will be able to better utilize it, we have abided by Albert Einstein's admonition that *Everything should be made as simple as possible, but not simpler*. Thus, little of this book would qualify as light reading, and some may wish to skip some parts of it. In fact, it was written to be accessible in whole or in part, and each chapter can stand alone. For those who want a more general overview absent the underlying technology, other references exist, but we are confident that those who are willing to read all or most of this book will find it well worth the effort.

While each chapter can be read in isolation from the rest of the book, we have included cross-references between chapters to help the reader integrate the various components into the whole of image-guided surgery (IGS). Chapter 1, "Brief History of Image-Guided Surgery", traces the development of IGS from Roentgen's discovery of x-rays through development of computed tomography (CT) and magnetic resonance imaging (MRI) and on to the current level incorporating tracking systems allowing navigation on CT and MRI images while operating. Chapter 2, "CT and MRI", covers the basics of CT and MRI, including explicit presentations of the limits of imaging technology. Chapter 3, "Tracking Systems", investigates optical (infrared and visual)

and electromagnetic tracking of objects—a necessary requirement for IGS. Chapter 4, "Registration", explains how a CT or MRI image is superimposed onto intraoperative anatomy. Chapter 5, "Error Analysis", treats the ubiquitous errors that exist in all IGS systems, and it provides explicit recommendations of ways in which a surgeon can minimize those errors. Chapter 6, "Best Practices for Use of IGS", debates the evidence supporting the use of IGS in clinical settings. Chapter 7, "Surgical Systems", presents currently approved IGS systems and expected accuracies based on laboratory and clinical studies. Chapter 8, "What Does the Future Hold?", discusses likely short- and long-term uses of IGS, including augmented reality and robotic applications.

The 21st century is still young but already promises to be a century noted for technological progress in medicine. Image guidance in surgery will certainly continue to be a big part of that progress, and new systems with new capabilities will steadily appear. As they do, the field may seem to grow more and more daunting, but the foundations of this field are in fact likely to remain the same. And, the practitioner who has mastered those foundations should be able to keep abreast of the changing landscape. We hope that this book will help guide you through that landscape, and we look forward to hearing from you, and about you, as you master these marvelous tools, as you use them in surgical interventions, and as you improve them to advance the future of medicine.

Rob Labadie
robert.labadie@vanderbilt.edu
rflabadie@gmail.com

Mike Fitzpatrick
j.michael.fitzpatrick@vanderbilt.edu
fitzpatrickmike0@gmail.com

ACKNOWLEDGMENTS

Like most first-time authors (and despite admonitions from my veteran coauthor!) I grossly underestimated the amount of effort required to write a book. Having survived the journey, I am deeply indebted to the many who helped me along the way. First and foremost is my immediate family, especially my wife Karyn, who dealt with my fluctuating moods during the highs and lows of the project. Our four boys were supportive but thought it was just another one of dad's crazy ideas. I thoroughly enjoyed bouncing ideas off our oldest son, an undergraduate physics major, over lunches during his summer internship at Vanderbilt in 2015.

This project could not have transpired without a sabbatical—rare for an academic surgeon—which my chair, Ron Eavey, granted me for six weeks in January and February of 2015. During this time, my clinical colleagues, especially the neurotology service consisting of David Haynes, Marc Bennett, George Wanna, Alejandro Rivas, and Ken Watford, DNP; my nurse, Georgette Smiley, RN; and multiple other nurses, residents, and fellows who covered patient emergencies and urgencies, allowing me the privilege of protected time dedicated to the project. My administrative assistant, Maria Ashby, retired in the midst of the project but substantially started the enormous task of obtaining figure permissions. This task was carried forth by our newly hired lab manager, Jody Peters, who both finished that task and also proofread the entire manuscript. Thanks also to Plural Publishing—namely, Valerie Johns, Kalie

Koscielak, Megan Carter, and Nicole Bowman—for taking a chance on a book of this topic and for editorial and publishing expertise.

I am sure this project would never have reached its conclusion without the continual prodding, critiquing, and encouraging of my coauthor, Mike Fitzpatrick. When I arrived at Vanderbilt in 2001 and met Mike (Bob Galloway, now Professor Emeritus of Biomedical Engineering, introduced us), little did I know how entwined our careers would be although on different ends of the career spectrum as I was but a naïve assistant professor and he was a sage full professor. Over the 15 years we have worked together, I have learned more from him than anyone else at Vanderbilt both about image-guided technology and about navigating academia. Our relationship has thrived based on our mutual respect for each other's expertise yet the freedom to propose any idea. (The fact that we have a lot of fun working together only adds to the experience!) I am honored he choose to share the byline with me on this textbook.

Another benefit of working with Mike was that I became integrated into the School of Engineering at Vanderbilt University through which I have had numerous fruitful collaborations many of which have had a direct impact on this book including those with Michael Goldfarb, PhD, Ramya Balachandran, PhD, Benoit Dawant, PhD, Jack Noble PhD, and Bob Webster, PhD. Collaborations such as these between surgeons and engineers may seem obvious but

often are impeded by the lack of shared resources and/or misaligned incentives within academia. Lucky for us at Vanderbilt, such collaborations have been encouraged and supported through the Vanderbilt Institute of Surgery and Engineering which receives generous internal and external funding to facilitate advances in health care outcomes based on implementation of engineering technology (<https://www4.vanderbilt.edu/vise/>).

Finally, I must state that this book is a huge “badge of honor” to me perhaps

born out of my heritage, most especially my aunt and godmother, Bernadine Meyer, a retired business law professor who wrote *Legal Systems* in 1978 and incorporated all members of our extended family into case studies (I was the president of a labor union and witness to an industrial accident) and my uncle and namesake, Fr. Earl (Robert) Meyer, who had *Homilies of Father Earl Meyer* published in 2013, 2014, and 2015. It is with great pride that I add *Image-Guided Surgery: Fundamentals and Clinical Applications in Otolaryngology* to this list!

—Robert F. Labadie

Many people helped me along the path toward this book. Professor Edward Desloge was first. He had a profound influence on my writing and teaching as my PhD advisor in physics at Florida State University. I defended my dissertation in 1972 only a few months after Godfrey Hounsfield announced the invention of computer-assisted tomography. Desloge sagely advised me to enter the burgeoning field of medical physics, but I was young and foolish and ignored that advice—for nine years.

In 1981, while I was on a sabbatical from teaching undergraduate physics, I met Professor Stephen Pizer of the Department of Computer Science at the University of North Carolina. His inspiring enthusiasm for medical image processing, which combined physics, computers, and medicine, finally won me over. I quit my tenured position, earned a master’s degree in computer science, and with Steve’s help landed an assistant professorship in computer science at Vanderbilt University.

Just five years later, Dr Robert Maciunas, a recently hired surgeon at Vanderbilt, walked into my office, introduced himself, began divulging some exciting ideas for improving brain surgery, and suggested that we might work together to make them happen. I took the plunge, and after 12 years, on the basis of that work, I was awarded a full professorship at Vanderbilt and he was awarded a chairmanship in New York. It was 1999, and I was now prepared for a relaxed glide path into retirement in the new century.

Instead, the curtain was about to rise on major new phase of my life. Just two years after Bob Maciunas left, a new person appeared, bringing with him a hefty dose of *déjà vu*. Dr Robert Labadie, a recently hired surgeon at Vanderbilt, walked into my office, introduced himself, began divulging some exciting ideas for improving ear surgery, and suggested that we might work together to make them happen. Rob Labadie had a tougher sell than

Bob Maciunas. My position was secure, I was only nine years from retirement, and I was reluctant to tackle yet another region of anatomy. However, one need experience the Labadie personality but once to understand why I was swept along. I have never met a more persuasive, enthusiastic, optimistic, amiable, kind, and brilliant person. And there was another factor—Rob Labadie is a surgeon who understands physics *and* mathematics! So I took another plunge. We formed a team, and, with this book, we are completing our 15th year of a collaboration that has been the most successful of my career—and the most fun.

All four of these people shared important ideas with me and encouraged me, and as a result I owe them a huge debt of gratitude for any success that I may have had, but others have shared ideas with me as well. First, there are the many graduate students that I have had the pleasure to advise over the last 30 years, including my dear friend Dr Ramya Balachandran, who, upon receiving her PhD in computer science in 2008, worked with Rob and me

as a research assistant professor. I am indebted to many other colleagues as well, both inside and outside Vanderbilt with whom I have collaborated for over 25 years, most notably Professor Benoit Dawant of Electrical Engineering, Professor Emeritus George Allen of Neurological Surgery, and Professor Emeritus Robert Galloway of Biomedical Engineering. I thank them all.

Finally, I wish to thank my dear wife, Dr Patricia Robinson, who put up with many lonely evenings and weekends while Rob and I worked on this book and who, despite a busy pediatric practice, has supported my career every inch of the way and has given me two wonderful children. Pat continually amazes me both with her deep and abiding concern for her patients and with her extraordinary deductive powers when the data are so sparse and the diagnosis is so crucial. The way she practices medicine reminds me daily that while the marvelous technological breakthroughs described in this book represent major advances in health care, the most important tool will always be the human mind.

—J. Michael Fitzpatrick

BRIEF HISTORY OF IMAGE-GUIDED SURGERY

Overview of How Image-Guided Surgery Works

Anyone who has learned to drive within the past decade probably thinks of a paper map as a museum artifact and is unlikely to navigate anywhere without using a global positioning system (GPS). Similarly, current surgical trainees are unlikely to practice without image-guided surgical (IGS) systems, which are often compared to GPS albeit on a smaller scale in the operating room. And who wouldn't want to have this amazing technology available to see things inside the human body and know precisely where those things are? Who doesn't want Superman's x-ray vision? But, as the mythical Superman understood, with great abilities come great responsibilities, and in the surgical arena, this means understanding how IGS works so that surgeons know the limits of the technology—when to trust IGS and

when to trust anatomical knowledge. Although the comparison between IGS and GPS is useful in conveying what each technology can do, there are some fundamental differences between the two (see boxed text Chapter 3). One useful similarity, however, is how—despite their obvious benefits—they can get users into trouble—for example, the naïve driver who does not understand the limits of GPS while operating at the limits of his or her knowledge of the terrain and trusts it when it recommends a shorter route over a mountain pass in inclement weather or the naïve surgeon who does not understand the limits of IGS while operating at the limits of his or her surgical skills and trusts it when it puts the crosshairs inaccurately on the surgical target, erroneously guiding the surgeon to remove vital tissue.

Image-guided surgery (IGS) involves linking a preoperative image, most commonly computed tomography (CT) or magnetic resonance imaging (MRI),ⁱ

ⁱIn this book, we will consider only CT and MRI because these are the imaging modalities overwhelmingly used for IGS in otolaryngology.

to a patient's intraoperative anatomy, allowing one to navigate using the image as a guide or map. Current IGS systems are more similar than different among various vendors (Chapter 7), and all use tracking both to identify points that will be used to register the preoperative image (Chapter 2) to the patient's location in the operating room and to navigate during surgery (Figure 1–1). Tracking (Chapter 3) may take the form of opticalⁱⁱ tracking, which localizes via triangulation, in which dimensions of virtual triangles connecting known points with an unknown point are solved using geometry, or the form of electromagnetic tracking, in which a probe disrupts an electromagnetic field (EMF) and the disruption can be correlated

to position. Some tracked points are denoted as fiducials (Chapter 4), which may consist of unique patient anatomy or of markers affixed to the patient. The locations of fiducials are specified in the preoperative image (Chapter 2) and, after they are localized in the operating room using the tracking system (Chapter 3), the two sets of locations are overlaid onto each other in a process known as registration (Chapter 4). After registration is performed, a tracked probe can be used to navigate in the surgical space, which is registered to the image space, and it is this registration plus tracking that makes IGS possible.

Sounds simple—right? Well . . . the underlying concepts are sound, but *Le*

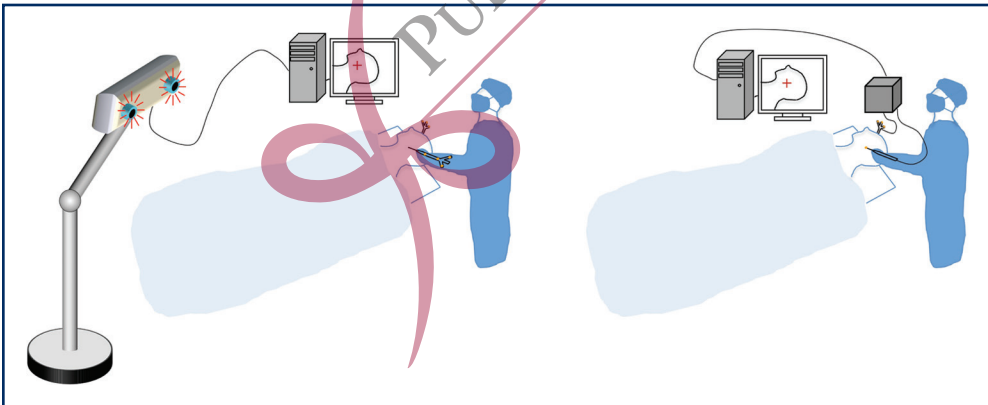


Figure 1–1. A generic optical tracking IGS system is shown at the left and a generic EMF IGS system is shown at the right. The surgeon stands opposite a video monitor that shows the position of the tracked probe on a preoperative image such as a CT or MRI. For the optical system, an infrared camera system sends out pulses of infrared light that reflect off markers attached to the probe, held by the surgeon, and a coordinate reference frame (CRF), affixed to the patient to allow tracking of the head; depicted is the more common “passive system”, which does not require hardwiring between the tracked devices (the probe and the CRF) and the computer. For the EMF system, the probe is usually hardwired to the EMF generation unit, shown as a gray cube. Tracking systems are discussed in more detail in Chapter 3.

ⁱⁱIn this book, unless indicated otherwise, “optical” denotes the portion of the electromagnetic spectrum that can be directed and focused by means of conventional lenses and mirrors (eg, visible and infrared light).

*bon Dieu est dans le detail!*ⁱⁱⁱ Be you an optimist or a pessimist, the details of IGS are vital in minimizing error (Chapter 5)—which never goes away—and ignoring these details accounts for the vast majority of misuses of IGS. But, we’re getting ahead of ourselves because to appreciate current IGS systems, we need to learn how we have arrived at a world where IGS systems are all but ubiquitous in modern operating theaters.

The Evolution of IGS

Images

Without images, there would be no image-guided surgery, so the history of IGS is intimately linked to the history of radiology, which had its seminal event in 1895 on November 8 when Wilhelm Conrad Röntgen discovered x-rays (called “x” to designate an unknown) at the University of Würzburg, Germany. Two weeks after his initial discovery (and without institutional review board approval!), he captured a now famous image of his wife’s hand (Figure 1–2). Although he knew that the commercial potential was huge, Röntgen decided against patent protection because he felt that his discovery belonged to humankind. His findings were published December 28, 1895, and he was awarded the first Nobel Prize in Physics in 1901. He donated the prize money to the University of Würzburg.

Röntgen’s discovery had a surprisingly quick bench-to-bedside transition being used early the next year, 1896, for multiple applications. J. H. Clayton of

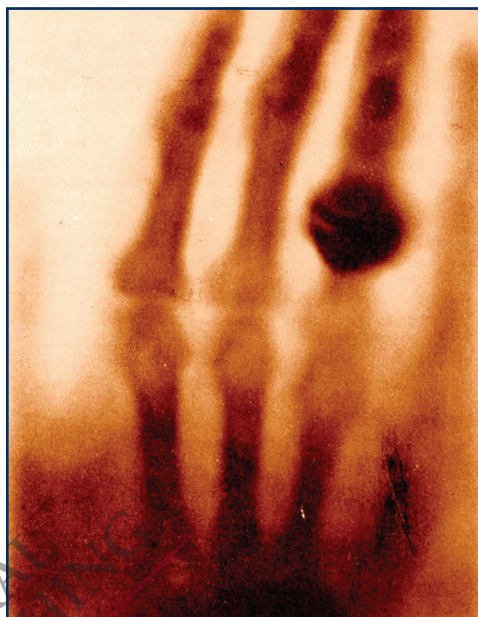


Figure 1–2. The first known x-ray image produced by Röntgen of his wife’s hand at the University of Würzburg, Germany (albeit without ethical board approval!).

Birmingham, England, is given credit for the first IGS intervention, which occurred a mere eight days after the publication of Röntgen’s discovery. Clayton used an x-ray machine to identify an industrial sewing needle embedded in a factory worker’s hand and to assist him in its removal.¹ IGS crossed the Atlantic one month later when John Cox at McGill University in Montreal, Canada, used an x-ray image to remove a bullet from a limb,² and in America, in February 1896, a New York surgeon, Dr Bull, asked physicist Michael Pupin to obtain an x-ray image of the hand of a patient with embedded buckshot to assist in its removal³ (Figure 1–3). Otolaryngology’s ties to this history began early when the first Department

ⁱⁱⁱGustave Flaubert, 19th century, *God is in the detail*. This original quote is the origin of today’s *The devil is in the details*.

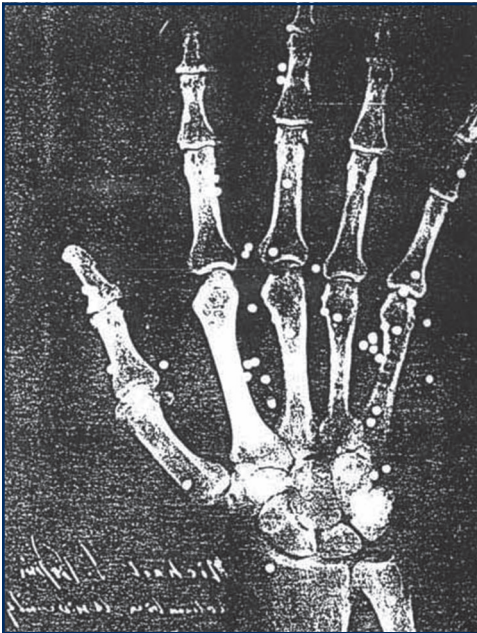


Figure 1–3. An early x-ray image taken by physicist Michael Pupin circa 1896, which was used by Dr Bull to extract buckshot from the patient's hand. This greatly facilitated the intervention that was performed quicker than anticipated.

of Radiology at the Glasgow Royal Infirmary (Glasgow, Scotland) was established in 1896 by laryngologist John Macintyre, who imaged, among other things, a coin in a child's throat.⁴ Military applications followed quickly, when x-rays were used to find and treat both fractures and embedded shrapnel, first during the Italo-Abyssinian War and subsequently the Boer War and World War I.⁵ Although multiple other uses were conceived of during the early part of the 20th century, IGS was hampered by the need for three-dimensional depictions instead of the two-dimensional shadows produced by x-ray projection. The third dimension would come in the third quarter of the 20th century with

the discovery of computed tomography and magnetic resonance imaging.

Discovery of CT

In 1967, while the Beatles were working on their groundbreaking album, *Sgt. Pepper's Lonely Hearts Club Band*, for release by Electric and Musical Industries (EMI), Ltd., another groundbreaking development was taking place inside the same company. While EMI was prospering from the profits generated by the Beatles phenomenon,^{6,7} an EMI engineer, Godfrey Newbold Hounsfield, was working stealthily on the first CT scanner. By 1968, he had completed a working prototype that proved the concept and had submitted a patent application that would be granted in 1971. In 1973, EMI announced the world's first working clinical model.⁸ Its images were crude and required two days to compute, but it revolutionized diagnostic medicine and surgery and led ultimately to today's remarkable instruments. Early clinicians were amazed by the EMI image (Figure 1–4). Mike Glasscock, founder of the Otology Group in Nashville, Tennessee, recalls, for example, that it allowed him—for the first time ever—to be able to see how big a vestibular schwannoma was prior to beginning the surgery. Thus, he could plan his surgical approach and estimate time of intervention *before* cutting skin.

Today, continual improvements in CT seem nowhere near their end. But neither was Hounsfield's work the beginning. The idea of combining radiographic information of a patient acquired from multiple directions to produce a picture of a single slice ("tomos" =

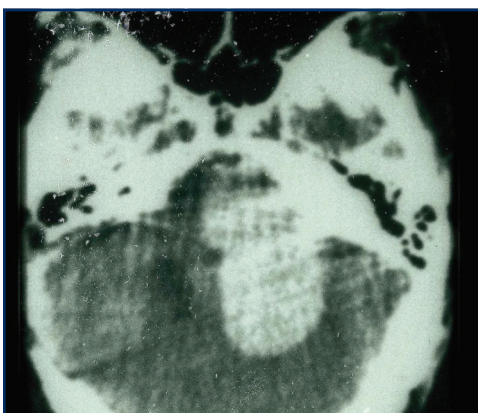


Figure 1–4. An early EMI scan circa 1975 from Dr Michael Glasscock’s practice in Nashville, Tennessee, showing a large left-sided vestibular schwannoma. Such images, although considered “rough” by today’s standards, allowed surgeons to predict how long a surgical intervention might take.

slice; “graphy” = producing a picture) through the body was born a half century earlier. In 1917, just over 20 years after Röntgen’s discovery of x-rays, André-Edmund-Marie Bocage conceived of x-ray tomography.⁸ In 1921, he applied for a French patent on the idea, which was issued in 1923, and by 1940, nineteen additional tomography patents had been awarded. More were to follow, and by the time Hounsfield began his work on his prototype at EMI, over 3000 articles had been published on it and over 50 commercial tomographic imagers had been introduced. At that time, in the late 1960s, over 60% of the radiologists in the United States had one, but they used them in only 1% of their cases!⁸ Why?—because the images of these slices through the body were badly blurred by shadows of remote parts of the body. Tomography from 1917 to the 1960s was nothing

like the tomography of today. Those largely unused imagers produced their slice images by directing x-rays roughly perpendicularly to the slice, similarly to plain-film radiography, and as a result, the tissue overlying and underlying that slice added confusing shadows that confounded the desired tissue slice with irrelevant anatomy. This corruption of the image is an inherent problem with any approach to x-ray tomography because the signal produced in each sensor, whether it is a grain of x-ray film, a phosphor, or a silicon chip, is produced by the cumulative effect of everything the x-ray encounters along its path through the body. It is up to the imaging device to tease out the true individual intensities at each of the points within a slice from these integrated signals.

Early researchers in the field of x-ray tomography were well aware of the problem, and in 1940, a major step toward solving it was invented and patented by Gabriel Frank.⁸ Frank approached slice imaging from a different angle—literally! His rays were projected not perpendicularly to the slice but sideways, into the edge of the slice, and they traveled entirely within the slice, and—most important—never passed through any anatomy *outside* the slice. Frank’s patent describes an ingenious photographic process not only for acquiring such projections from multiple angles (by rotating the patient) but also for combining those projections via a second photographic projection (by rotating a cylinder of film) to produce a tomogram. His method was not implemented, but if it had been, while it was a giant step beyond the prevailing approaches, the image would still