


Pediatric Voice

A Modern, Collaborative Approach to Care



Lisa N. Kelchner, PhD, CCC-SLP, BRS-S
Susan Baker Brehm, PhD, CCC-SLP
Barbara D. Weinrich, PhD, CCC-SLP



Contents

<i>Acknowledgments</i>	<i>xi</i>
<i>Contributors</i>	<i>xiii</i>
Chapter 1. Introduction	1
Chapter 2. Anatomy and Physiology of the Pediatric Upper Aerodigestive Tract, Larynx, and Respiratory System	3
Overview	3
Anatomy of the Upper Respiratory System: Overview of Embryologic Development	3
Anatomy of the Upper Aerodigestive Tract: Overview of Postnatal Anatomy and Developmental Changes	5
Anatomy and Physiology of the Upper Aerodigestive Tract	7
Nasal Passages	7
Pharynx	8
Esophagus	8
Larynx	11
Vocal Fold Microstructure	23
<i>Contributed by Keiko Ishikawa</i>	
Basics of Histology	25
Vocal Fold Histology	26
Developmental Changes in the Vocal Fold Across the Lifespan	28
Fetus and Infant	29
Young Children	29
Adolescents	30
Older Adult and Elderly	30
Pediatric Respiratory Anatomy and Physiology	31
Anatomy and Physiology of the Lower Respiratory Tract	31
Tracheal Airway	31
Bronchioles/Bronchi	33
Lungs/Thoracic Cavity	33
Muscles of Respiration	34
The Physiology of Breathing	35
The Physiology of Phonation	36
The Basics	36
Theories of Phonation	37
Pitch and Intensity Changes	39
Resonance	40
Chapter Summary	41
References	41

Chapter 3. Neural Controls of Voice	45
Overview	45
Vocalization and the Infant Cry	45
Central Neural Controls	47
Brainstem	47
Cortical and Subcortical Controls	49
Peripheral Neural Controls	52
Cranial Nerves	52
Laryngeal and Pulmonary Reflexes	55
Pediatric Voice and Disorders of the CNS	56
Chiari Malformation	57
Cerebral Palsy	57
Movement Disorders	58
Voice and Autism Spectrum Disorder	59
Chapter Summary	60
References	60
Chapter 4. Etiology and Management of Pediatric Voice Disorders	63
<i>Contributed by Alessandro de Alarcon</i>	
Introduction	63
Pediatric Voice Disorders: Risk Factors and Symptoms	63
Common Vocal Fold Pathologies	63
Vocal Fold Nodules, Cysts, and Polyps	63
Management	65
Vocal Fold Process Granulomas	67
Management	67
Vocal Fold Paralysis	67
Unilateral Vocal Fold Paralysis	67
Management	68
Bilateral Vocal Fold Paralysis	70
Management	71
Laryngeal Webs	72
Management	72
Recurrent Respiratory Papillomatosis	73
Management	73
Laryngopharyngeal Reflux and Eosinophilic Esophagitis	74
Management	74
Sulcus Vocalis and Vocal Fold Scar	74
Management	75
Chapter Summary	75
References	75

Chapter 5. A Collaborative Approach to Evaluating the Child with a Voice Disorder	79
Overview	79
Evaluation Models and Approaches	79
The Solo and School-Based Practitioner with Otolaryngology Referral	80
Screenings	81
The Medical Evaluation	81
Oral Peripheral Examination	81
Hearing Screening	83
Background and History	83
Significant Medical History	83
Vocal Hygiene	83
Vocal Symptoms	84
Airway History	84
Behavioral Questions	84
Special Circumstances	84
Assessing Impact: Handicapping and Quality of Life Indicators	85
Perceptual Evaluation	86
Instrumental Assessment	87
Acoustic Analysis	88
Aerodynamics	95
Electroglottography	99
Endoscopic	100
Pulling It All Together: Case Summaries	103
Case 1. Hospital-Based Clinician	103
Case 2. School-Based Clinician	104
Case 3. Private Practice Clinician	106
Chapter Summary	106
References	106
Appendix 5–A. Initial Intake History Form	111
Appendix 5–B. DVD Table of Contents	117
Chapter 6. A Collaborative Approach to Treatment	119
Overview	119
Collaborative Treatment Model	119
Solo or School-Based Practitioner	120
Making the Case	120
Communicating with Teachers and Others	121
Pediatric Voice Disorders and Their Identification Under IDEA	121
Access to Professional Care	122
Establishing a Connection with Child and Family	122

Indirect Treatment Methods	122
Direct Treatment Methods	123
Vocal Function Exercises	124
Resonance Therapy	126
Methods Based on Semiocclusion of the Vocal Tract	128
Additional Treatment Techniques	130
Adapting Adult Techniques for Children/Improving Compliance	131
Child and Adolescent Differences	131
Technology and Therapy	132
Gaming	132
Apps for Google Android and Apple iOS Devices	134
Telehealth and Pediatric Voice Therapy	136
Pediatric Performer: Considerations for Performing Voice—Childhood Through Adolescence	137
<i>Contributed by Wendy LeBorgne</i>	
Historical Vocal Pedagogy of Young Singers	137
Considerations for Singing During Puberty	139
Laryngeal Pathology in the Pediatric Performer	141
Pulling It All Together: Case Summaries	141
Case 1. Patient: Lancer (Bilateral Vocal Fold Lesions)	141
Case 2. Patient: Tom (Bilateral Vocal Fold Lesions)	143
Case 3. Patient: Elizabeth (Functional Voice Loss)	144
Case 4. Patient: Audrey (Anterior Laryngeal Web and Chronic High Pitch Voice)	145
Case 5. Patient: Todd (Therapy to Promote Supraglottic Voice Use)	146
Case 6. Patient: Zachary (Bilateral Vocal Fold Paralysis)	147
Case 7. Patient: Jeff (Subglottic Stenosis and Airway Reconstruction)	148
Chapter Summary	149
References	149
Appendix 6–A. Vocal Hygiene Guidelines	155
Appendix 6–B. Vocal Hygiene Record	157
Appendix 6–C. Gastroesophageal Reflux Information for Families	159
Appendix 6–D. Vocal Function Exercises Home Instructions	161
Appendix 6–E. Vocal Function Exercises Data Form	163
Appendix 6–F. Resonance Therapy Home Instructions	165
Appendix 6–G. Resonance Therapy Data Form	167
Appendix 6–H. DVD Table of Contents: Demonstration of Treatment Methods	169
Chapter 7. Managing Children with Complex Voice Disorders	171
Overview	171
Pediatric Airway Injury	171
Subglottic Stenosis	172
Pediatric Tracheotomy and Tracheostomy	172
The Role of the SLP in Caring for a Child with a Tracheostomy	174

Airway Reconstruction	179
Physical Findings and Voice Outcomes Post-Airway Reconstruction	181
Voice Evaluation for the Child Pre- or Post-Airway Reconstruction	183
Treatment of Dysphonia Following Airway Reconstruction	184
Pediatric Laryngectomy	186
Symptoms and Causes	186
Treatment	186
Paradoxical Vocal Fold Dysfunction	187
Symptoms and Causes	187
Diagnosis	188
Treatment	188
Puberphonia	189
Symptoms and Causes	189
Diagnosis	189
Treatment	189
Muscle Tension Dysphonia: An Overview	189
Pulling It All Together: Case Summaries	190
Case Summary 1. Patient: Sam (Pediatric Laryngectomy)	190
Case Summary 2. Patient: Katie (Paradoxical Vocal Fold Dysfunction)	191
Conclusion	193
References	193
Appendix A. Supplement on Wound Healing and the Vocal Folds	197
<i>Contributed by Keiko Ishikawa</i>	
Wound Healing and the Vocal Folds	197
Wound Healing Process	197
Factors that Influence Wound Healing	199
Vocal Fold Wound Healing and Scar	200
Voice Therapy and Wound Healing	201
References	201
<i>Index</i>	205

CHAPTER 1

Introduction

An infant's first cry is its announcement to the world that it has arrived. A loud, vibrant cry is the first indicator of a baby's health and well-being. Shaped by rapidly evolving skills, the voice of an infant conveys need, distress, and contentment. The future and integrity of that voice relies on an exquisite, highly timed, rapidly unfolding developmental process that works in coordination with neurologic, auditory, respiratory, and speech and language mechanisms. When an infant or child's development is interrupted or the mechanics of voice are altered, significant communication obstacles can occur. Understanding how the biologic, behavioral, and emotional functions of voice subserve communication and reflect health is an essential component of pediatric voice care.

A common phrase in pediatric medicine is that a child is not a miniature adult; that is, it is not enough to simply modify knowledge pertaining to adults and apply it to the care of children. Although the scientific underpinnings of voice production remain the same over the course of a lifespan, care of the pediatric voice requires knowledge of childhood developmental anatomy and physiology; growth and learning; educational, behavioral, parent, and family issues; and the potential for a voice disorder to have handicapping effects in classroom and social situations. More-

over, taking care of the pediatric population entails specific approaches to evaluation and treatment.

Interestingly, most instructors of graduate courses in voice disorders use textbook(s) that provide the fundamentals of voice care and principles of voice science framed by cases and examples derived from the adult population; relatively little emphasis is placed on childhood voice disorders and care. Yet, many students will work in an early intervention or educational work setting. Once in such settings, these newly trained professionals may lack confidence in assessing and addressing pediatric voice problems. Furthermore, in the school setting, care of the child with a voice disorder may be considered a low priority or may not be considered a hindrance or educational handicap at all. In view of these issues, this book is designed to guide the reader through the development of a well-defined knowledge base that is essential to successful clinical practice in pediatric voice.

Throughout the text the reader will note a strong emphasis on a collaborative approach to the care of children with voice disorders. The authors of this book are fortunate to be able to care for their patients in an environment in which physicians and allied health professionals work hand in hand to provide well-integrated, comprehensive care. We have,

however, kept in mind that many clinicians do not have that opportunity; this is reflected in some of the case-based examples we have presented.

This book follows a format that is similar to many traditional clinical disorder texts. The relevant anatomy and physiology, including the physiology of voice production, are reviewed in Chapter 2, followed by a discussion of pertinent neuroanatomy and physiology in Chapter 3. Chapter 4 covers all of the common (and some uncommon) etiologies associated with pediatric voice disorders and how they are medically and/or surgically managed. A comprehensive review of the pediatric voice evaluation is presented in Chapter 5, followed by a detailed discussion of treatment approaches in Chapter 6, which includes treatment and special considerations for the child performer as well. The final chapter is dedicated to the application and extension of information in the preceding chapters to the child who has a history of complex airway and voice disorders. Much of this chapter is dedicated to treatment and management considerations for children who were premature and were tracheotomized at one time. That is a population that will likely have a voice disorder that lasts a lifetime. Finally, an overview of wound healing is presented in an appendix at the end of the book. This section provides important information about the critical components of vocal fold injury and the process of tissue recovery at the cellular level.

The actual patient samples and examples we have provided are designed to offer some experience, in the sense that the reader will have the opportunity to do both auditory-perceptual and video-imaging ratings. We hope that listening and in some cases rating the samples will provide spe-

cific insights and suggestions for the graduate student, as well as the school-based and solo practitioner. Each chapter contains an in-depth discussion of the fundamentals required to provide appropriate, high-quality care. *Why* a specific treatment approach is decided upon is as important, if not more so, as *how* a management plan is carried out. Although technical skills develop with experience, failure to understand the rationale of a treatment approach or technique will limit a clinician's ability to provide the best possible care. Providing optimal care almost always involves blending evidence supported, time-tested approaches with new trends. We have included updates on the ever-changing technology used in assessment and treatment, as well as novel models of voice care delivery, such as gaming and telehealth options. At the end of Chapters 5 (evaluation), 6 (treatment), and 7 (complex voice and airway patients), the reader will find case study examples that build upon knowledge presented in the text. The reader will also find "clinical notes" throughout some chapters that highlight important clinical concepts and extend knowledge in specific areas. In some chapters the reader will find references to the accompanying DVD that provides opportunities for practice of audio-perceptual ratings and stroboscopy ratings. Additional written, video, and audio examples of specific evaluation and therapy techniques are included on the DVD as well.

In conclusion, the purpose of this textbook is to provide practical information that is applicable to the clinician providing pediatric voice care. It is our hope that the insights gained will facilitate improved, comprehensive care of children with voice disorders in both early childhood and school-age educational settings.

CHAPTER 2

Anatomy and Physiology of the Pediatric Upper Aerodigestive Tract, Larynx, and Respiratory System

Overview

The laryngeal airway has three primary biologically related functions: (1) serving as a conduit for airflow during ventilation; (2) valving or sealing (and thus separating the upper from the lower respiratory tract) for airway protection or to increase subglottic pressure for straining and lifting; and (3) generating sound for phonation. Understanding the hierarchy of these functions is essential, as the order of their importance can determine needed interventions. For example, establishing a patent or adequate airway in a child is essential to survival and thus will be managed over voicing needs. This issue is revisited several times throughout this book as medical-surgical interventions and outcomes are presented.

This chapter provides the necessary fundamental information related to the anatomy and physiology of voice in the developing child. A child is not a miniature adult; therefore, an understanding of the rapid changes involving the structures and functions of the

laryngeal and respiratory systems across childhood is required. A discussion of the anatomy and physiology of the head and neck is presented including the primary skeletal structures or framework (bones and cartilage), spaces, muscles, blood supply, nerves (innervation), and mucosal membranes. Of note, because the anatomy and the physiology of the oral cavity, tongue, and face are covered in basic anatomy courses that information is not repeated here. This section includes information about typical embryologic and postnatal development of the upper aerodigestive tract and lower respiratory tract structures, laryngeal histology, and the physiology of phonation. Specific information about the neural controls is covered in Chapter 3.

Anatomy of the Upper Respiratory System: Overview of Embryologic Development

To best understand the structures and what they do, it is important to first review their

embryology. The transformation of the human embryo to newborn requires an elaborate, complicated, and exquisite biologic series of highly timed events. The respiratory system appears at approximately 3 weeks postconception (Larsen, 1993) following the differentiation of the embryo's rostral (toward the head) and caudal (away from the head) ends and the earliest development of the neural tube. The appearance of the pharyngeal arches (Figure 2–1) occurs at 4 weeks and will ultimately become the structures of the pharynx and the larynx. There are six pharyngeal arches; however, the fifth is considered rudimentary (Moore, 1992).

Pharyngeal arches are also referred to as branchial arches, a term that links embryologic development to primitive evolutionary processes. For every (outer) pharyngeal arch there is a corresponding (inner) pharyngeal pouch. Between the pharyngeal arch/pouch is a pharyngeal cleft. Each arch has a central core of mesenchyme or mesoderm, which is the cellular (or germ) layer between the endoderm (innermost germ layer) and ectoderm (outermost germ layer). Mesoderm gives rise

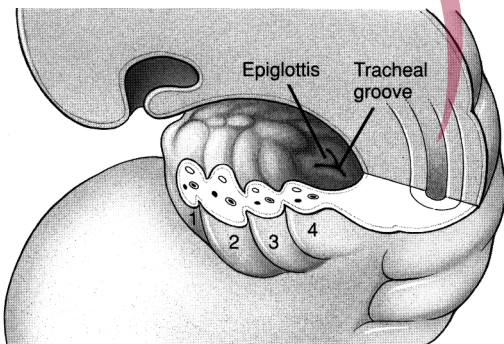


Figure 2–1. Cutaway view of the floor of the embryonic pharynx at approximately 4 weeks, showing pharyngeal arches 1 through 4, the laryngotracheal groove, and the origin of the epiglottis. From Myer, Cotton, & Schott, 1995. Reprinted with permission from Lippincott, Williams & Wilkins.

to connective tissue, muscles, bone, and circulatory and urogenital systems. Ectoderm gives rise to the epidermis (skin) and epidermal tissue, including the nervous system, glands, and mucous membranes of the mouth. Endoderm gives rise to the epithelial linings of the respiratory and digestive tracts as well as internal organs (e.g., liver and pancreas) and some glands.

The cartilaginous and bony structures of the face, mandible, larynx, and trachea arise from the mesoderm of the first, second, third, fourth, and sixth pharyngeal arches. The corresponding ectoderm gives rise to the cranial nerves, and the endoderm gives rise to respiratory and digestive tract organs as well as certain glands (Table 2–1).

The embryo to fetal transformation begins at week 8 and by that time the differentiation of the laryngeal cartilage and muscles is well under way (Bluestone et al., 2003; Larsen, 1993). Morphologically, all of the structures of the larynx, trachea, and digestive tract are present by (fetal) week 12 or the end of the first trimester. At this point, all of the structures are in their relative postnatal positions, although not fully developed, and the larynx and pharynx should now be a continuous recanalized tube. In months 3 through 6, intrauterine growth of the pharynx and trachea and midline fusion of the larynx occur along with differentiation and maturation of the muscles, nerves, and glandular structures. By the seventh month, the upper aerodigestive tract, including the laryngeal apparatus, is prepared to perform necessary biologic functions of life (Bluestone et al., 2003).

Observations of physiologic activity involving the head and neck have been observed via ultrasound technology. Between the ages of 9 and 12 weeks, the fetus is observed to swallow (amniotic fluid), produce suckle motions, and demonstrate respiratory movement of the pharynx, larynx, and diaphragm. After 13 weeks, activities such as lip opening, finger

Table 2–1. Developmental Overview of Early Embryologic Development of the Pharyngeal Arches and Grooves

<i>Arch/Pouch</i>	<i>Endoderm</i>	<i>Mesoderm</i>	<i>Ectoderm/Arch</i>
1st	Epithelial lining of the oral cavity, glands of anterior oral cavity	Bones of the upper and lower jaw MM mastication	CN V, trigeminal
2nd	Palatine tonsils, thyroid gland	Upper portion of hyoid bone MM facial expression Tongue	CN VII, facial
3rd	Epithelial lining of the pharynx, thymus gland	Contributes to hyoid Stylopharyngeus	CN IX, glossopharyngeal
4th	Lining of the hypopharynx, esophagus	Laryngeal cartilages Pharyngeal constrictors, levator vili palatine	CN X, vagus (superior laryngeal)
6th	Lining of the larynx, trachea, esophagus	Laryngeal cartilages Intrinsic laryngeal MM Striated MM of the upper esophagus	CN X, vagus (recurrent laryngeal)

Legend: MM or mm = muscle.

suckling, and face touching can be observed (Miller, 2003). Failures of the embryologic and fetal developmental process at any time can result in structural and mechanical deficits that will be present at birth or observed dur-

ing fetal development via ultrasound. Given its multiple essential functions, the aerodigestive region is vulnerable to intrauterine developmental failures caused by environmental or congenital factors.

Clinical Note: Failure of the larynx to recanalize, or open as a tube, can present as congenital laryngeal or subglottic stenosis, laryngeal web, or, if it fails to fuse at midline, a laryngeal cleft. If there is restriction of the laryngeal airway, a newborn infant will have difficulty breathing and a distinctly different cry (e.g., high pitched, weak). In the case of a deep laryngeal cleft, there may be problems with airway protection during feeding, as liquid can enter the posterior larynx below the level of the true vocal folds (TVFs).

Anatomy of the Upper Aerodigestive Tract: Overview of Postnatal Anatomy and Developmental Changes

At birth, the anatomy of the infant's head and neck include the same "parts" as that of an older child and adult, but they are proportioned differently and are not yet controlled by sophisticated, established sensory motor pathways. The infant skull is softer and not completely fused, and the position of the mandible is relatively level with the skull base (Meyer, Cotton, & Shott, 1995). The oral cavity is smaller and the tongue fills much of

the oral cavity space. The pharynx is short and the position of the larynx within this region is relatively high and approximates cervical spine levels C1–C4. The epiglottis is upright with its tip able to touch and interlock with the velum during feeding. The cartilage of the larynx is softer and its dimensions are approximately one-third that of an adult. In particular, the thyroid cartilage is more rounded and close to (and may overlap with) the hyoid bone. Within the larynx, the arytenoid cartilages are proportionately larger than the membranous portion of the true folds and appear bulky (Bluestone et al., 2003; Meyer et al., 1995). The length of the membranous portion of the vocal folds is approximately 1.3 to 2.0 millimeters (mm), with another 1 to 1.4 mm of cartilaginous portion (Hartnick & Bosley, 2008). Importantly, the respiratory epithelium that lines the larynx is mature but has a different distribution of ciliated epithelium and swells more easily (Meyer et al., 1995). The anterior to posterior distance of the pediatric glottic space is approximately 7 mm, with an approximate posterior width of 4 mm (Bluestone et al., 2003). The actual vocal folds comprise mostly the cartilaginous portion, favoring respiratory over phonatory function. At this time the subglottic region (within the ring of the cricoid) measures approximately 4 mm across. The trachea of an infant is approximately 4 cm in length and highly compliant, which can make it more prone to collapse. Within the digestive tract, the esophagus of a newborn functions with less precision than that of an older child or adult. Newborns are more prone to reflux and regurgitation, in part because the neural controls for peristalsis and the upper and lower esophageal sphincters (especially lower), are underdeveloped.

Within the first 2 to 3 years of life, there is considerable growth of the head and neck region. The skull enlarges and the larynx begins descending in the neck, lowering to cervical level C5 from C2–C3. The distance be-

tween the epiglottis and velum increases and the epiglottis begins to flatten from a more curled configuration. Cartilaginous structures harden and the hyoid bone ossifies. The cricoid cartilage loses some bulk and arytenoids reduce in their relative size to the rest of the glottis. The anatomic relationship of adult structures is generally in place in the child by age 6 to 7 years (Figure 2–2). Importantly, the microstructure of the vocal folds is beginning to differentiate from two to three layers of lamina propria (Hartnick & Bosley, 2008). There is continued growth of the larynx with increased weight and development of the child, and there is corresponding lowering of average fundamental frequency or pitch. These changes are gradual for both genders until the start of puberty. Throughout childhood, central and peripheral neural controls, along with the acquisition and mastery of speech and language skills, become more sophisticated.

During puberty, hormone-driven changes result in dramatic growth of the larynx, partic-

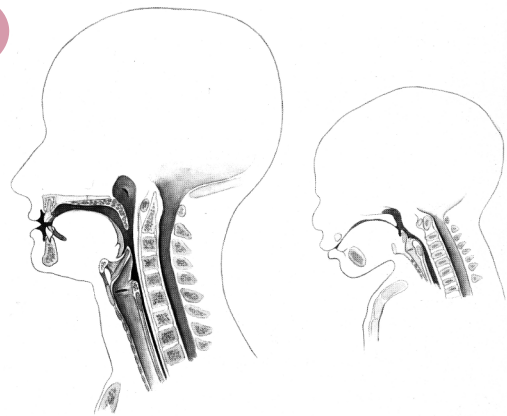


Figure 2–2. The adult larynx occupies a prominent position in the anterior neck. The cricoid ring lies approximately at the C-6 vertebral level. The cricoid ring in the young child is located at the C-4 vertebral level. From Myer, Cotton, & Schott, 1995. Reprinted with permission from Lippincott, Williams & Wilkins.

ularly in males, who will experience a significant increase in the prominence of the thyroid cartilage (commonly referred to as the Adam's apple). Throughout adulthood the angle of the thyroid cartilage in the female larynx remains flatter than that of same-aged males (Figure 2–3). In either gender, the position of the larynx in the neck descends to C6–C7. The membranous portions of the TVFs grow, reaching an adult length of 18 to 21 mm in males and 11 to 15 mm in females (Hirano, 1981). Moreover, the vocal fold layers as described above become more defined with age, reaching the full five layered histological composition around age 15 years (Hartnick & Bosley, 2008). For both genders, average fundamental frequencies lower for both genders, but the drop is especially striking for the peripubescent male. The rapid growth of the male larynx results in sudden, unexpected changes in pitch, referred to as pitch breaks. Across individuals, the rate and timeline of laryngeal growth and maturation vary, as does the rest of the pubertal changes and overall growth, but most young men's voices are sta-

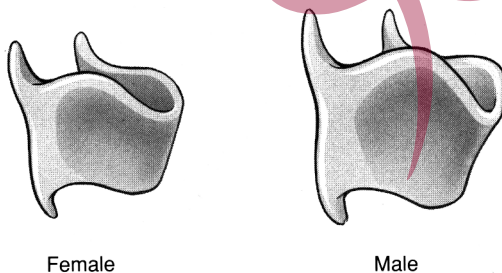


Figure 2–3. The female thyroid cartilage retains the rounded or gently angled appearance seen in the infant and young child. During puberty, the male thyroid cartilage laminae elongate and become acutely angled, causing the characteristic anterior prominence of the adult male thyroid cartilage. From Myer, Cotton, & Schott, 1995, p. 12. Reprinted with permission from Lippincott, Williams & Wilkins.

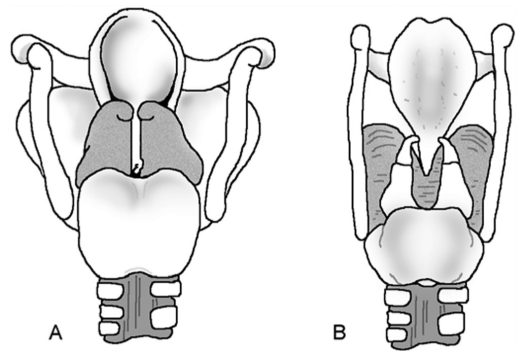


Figure 2–4. **A.** Posterior view of immature larynx and **B.** mature larynx. From *Voice Disorders* (2nd ed.) by C. Sapienza and B. Hoffman-Ruddy. Copyright © 2013 by Plural Publishing, Inc. Reprinted with permission.

ble by age 18 (Hollien, 2012) (see Figures 2–3 and 2–4).

Throughout adulthood, the laryngeal anatomy and physiology are relatively stable, with age-related changes occurring subtly and naturally over decades. In midlife and beyond, laryngeal changes can include ossification of the hyaline cartilages, weakening of the intrinsic muscles, thinning of the vocal fold cover, and changes to regional nerves and secretion-producing glands. Of course environmental, health, vocal use, and medical circumstances over the course of a lifetime can significantly impact vocal function later in life. Implications for diagnosis and treatment are discussed in later chapters.

Anatomy and Physiology of the Upper Aerodigestive Tract

Nasal Passages

Function

The primary function of the nasal passages is to filter and humidify inspired air and house the sensory nerve endings for olfaction, but